

# Short Communications

## Cutaneous TB caused by *Mycobacterium bovis* in a veterinary surgeon following exposure to a tuberculous alpaca (*Vicugna pacos*)

D. F. Twomey, R. J. Higgins, D. R. Worth, M. Okker, K. Gover, E. J. Nabb, G. Speirs

TUBERCULOSIS (TB) is an infectious disease caused by members of the *Mycobacterium tuberculosis* complex, which includes *Mycobacterium tuberculosis* and *Mycobacterium bovis*, as well as other *Mycobacterium* species (de la Rúa-Domenech 2006). *M. tuberculosis* is the primary cause of TB in human beings (Gallagher and Jenkins 1998). Although *M. bovis* is primarily a bovine pathogen, it can infect a wide range of animal species and human beings (O'Reilly and Daborn 1995). Of 276 human TB cases reported in south-west England in 2007, 78 (28.3 per cent) were confirmed by culture as *M. tuberculosis* and three (1.1 per cent) were confirmed as *M. bovis* (Tempest and others 2008). The number of *M. bovis*-associated human cases has significantly declined in developed countries, including the UK, as a result of national eradication programmes for cattle, supported by pasteurisation of milk (Gallagher and Jenkins 1998, Robert and others 1999, de la Rúa-Domenech 2006, Thoen and others 2006). Nevertheless, *M. bovis* still represents a zoonotic risk for those in close contact with infected animals, mainly as an occupational hazard of pulmonary TB in rural workers and abattoir staff (O'Reilly and Daborn 1995, Cousins and Dawson 1999, Robert and others 1999, de la Rúa-Domenech 2006). Transmission of *M. bovis* to human beings from non-bovine animals occurs only sporadically (de la Rúa-Domenech 2006).

Human cutaneous TB was a major problem in the late 19th and early 20th centuries but now accounts for only a small proportion of TB cases (Barbagallo and others 2002, Bravo and Gotuzzo 2007). It

is caused by *M. tuberculosis*, *M. bovis* and the bacillus Calmette-Guérin (BCG) vaccine (an attenuated strain of *M. bovis*). When *M. bovis* is involved, there is usually a history of occupational exposure (Gallagher and Jenkins 1998). This short communication describes a case of cutaneous TB caused by *M. bovis* in a veterinary surgeon following contact with a TB-infected alpaca (*Vicugna pacos*) in south-west England.

A healthy, BCG-vaccinated, 25-year-old female veterinary surgeon working in a mixed, mainly farm animal, practice examined a three-month-old cria from a herd of nine alpacas on several occasions. The cria had developed clinical disease characterised by lethargy and respiratory signs including wheezing, intermittent cough and increased respiratory noise on auscultation. Over 10 days following the first clinical examination, the respiratory signs worsened and the cria progressively lost weight despite treatment with a combination of enrofloxacin, bromohexine and frusemide. Thoracic radiography was carried out and revealed increased opacity of lung tissue consistent with a diffuse infiltrative disease process and possibly pleural effusion. The veterinary surgeon attempted thoracocentesis, which did not yield a significant amount of fluid. Due to the poor response to symptomatic treatment, the continuing decline in health, and the evidence of advanced lung pathology on radiography, the animal was euthanased on welfare grounds by intravenous injection of barbiturate.

The owner did not wish the animal to be subjected to a full post-mortem examination at a diagnostic laboratory, but requested that the veterinary surgeon carried out examination of the carcass at a disposal site. Multiple caseous lesions were observed in the lungs and thoracic lymph nodes. Representative samples of these tissues were fixed in 10 per cent formalin for histopathological examination, but fresh tissues were not collected for mycobacterial culture. Histopathological examination identified severe, chronic, active, granulomatous and necrotising mycobacterial pneumonia and lymphadenitis (Figs 1, 2). Variable numbers of slender acid-alcohol-fast bacilli were demonstrated in cold Ziehl-Neelsen (ZN)-stained sections of these tissues. Following the histopathological confirmation of TB, the case was notified to the local Animal Health office, in view of the possibility of notifiable disease associated with *M. bovis*, and the regional epidemiologist for human communicable diseases, in view of the possible zoonotic risk. Further statutory intervention was not required in the alpaca herd as no further cases occurred and *M. bovis* was not subsequently confirmed by culture.

The veterinary surgeon had worn protective gloves during the post-mortem examination and was not aware of any visible abrasions on her hands, nor did she knowingly cut herself over the period of contact with the cria. However, she had not worn gloves when euthanasing the cria and her hands had accidentally been contaminated with blood at the time of venepuncture. Six weeks after the post-mortem examination, she noticed a tingling sensation in the tip of her right thumb, but no lesion was visible at that time. After a further three weeks, a painful, circular, pale lesion approximately 4 mm in diameter developed at the site. Despite initial antibiotic treatment with cefalexin and amoxicillin/clavulanic acid, the thumb lesion enlarged and assumed a verrucous appearance (Fig 3), with associated swelling and pain in the elbow, lymphadenopathy of the trochlear and axillary nodes, and pyrexia. She was referred to North Devon District Hospital, where mycobacterial infection was suspected. The thumb lesion was curetted under local anaesthesia. Acid-alcohol-fast bacilli were seen by ZN staining of fresh tissue and, considering the possible involvement of atypical mycobacteria, ciprofloxacin and clarithromycin were prescribed. Thoracic radiography did not indicate pulmonary involvement.

Samples of the thumb lesion were processed for mycobacterial culture. Preliminary mycobacterial growth was identified by gene probe (AccuProbe *Mycobacterium tuberculosis* Complex Culture Identification Test; Gen-Probe) as a member of the *M. tuberculosis* complex and *M. bovis*

Veterinary Record (2010) 166, 175-177 doi: 10.1136/vr.b4780

**D. F. Twomey**, MVB, MRCVS,  
Veterinary Laboratories Agency –  
Starcross, Staplake Mount, Starcross,  
Exeter EX6 8PE

**R. J. Higgins**, BVMS, MSc, MRCVS,  
Veterinary Laboratories Agency –  
Lasswade, Pentlands Science Park,  
Bush Loan, Penicuik,  
Midlothian EH26 0PZ

**D. R. Worth**, BSc,

**M. Okker**, BSc,

**K. Gover**,

Veterinary Laboratories Agency –  
Weybridge, New Haw, Addlestone,  
Surrey KT15 3NB

**E. J. Nabb**, BVMS, MRCVS,  
Torbridge Veterinary Hospital,  
7 Caddsdow Industrial Park, Clovelly  
Road, Bideford, Devon EX39 3QT

**G. Speirs**, MBChB, FRCPath,  
Microbiology Department, Pathology,  
Level 1, North Devon District Hospital,  
Barnstaple, Devon EX31 4JB

E-mail for correspondence:  
f.twomey@vla.defra.gsi.gov.uk

Provenance: not commissioned;  
externally peer reviewed

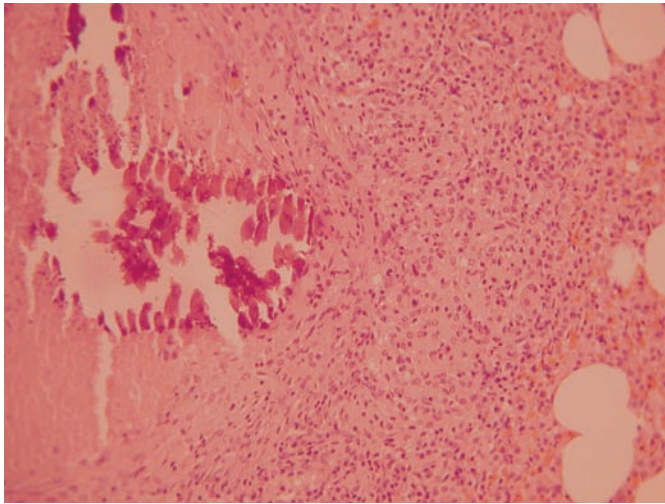


FIG 1: Lung of an alpaca cria, showing granulomatous and necrotising pneumonia. Haematoxylin and eosin. Original magnification x40

was subsequently isolated. When TB was confirmed by gene probe, 21 days after sampling, the skin lesion, which had regrown, was surgically debrided, and a six-month programme of anti-TB therapy was prescribed, comprising isoniazid, rifampicin and ethambutol. The symptoms resolved completely after this programme of therapy had started, and there has been no recurrence of mycobacterial disease at the time of writing, four years later.

Molecular typing of the *M bovis* isolate from the skin lesion was performed by spoligotyping (Kamerbeek and others 1997) and variable number tandem repeat (VNTR) typing using the exact tandem repeat loci (Hewinson and others 2006, Smith and others 2006). The human isolate was identified as *M bovis* spoligotype SB0140 (VLA type 9), VNTR 6-5-5-4\*-3-3.1.

The alpaca was considered to be a possible source of infection, and DNA was extracted from archived paraffin-embedded tissue sections from the alpaca for PCR testing. The target for the PCR assay was the multi-copy insertion element IS1081, which is present in six copies in members of the *M tuberculosis* complex. For confirmation of *M bovis*, primers were used that flank a specific deletion in the genome known as region of difference 4 (RD4), a single-copy target (Taylor and others 2007). PCR proved positive for the IS1081 insertion element showing that *M tuberculosis* complex DNA was present. However, the subsequent test for RD4 was not able to confirm that the mycobacterial species was *M bovis*.

*M bovis* has long been recognised as a zoonotic infection; most human cases in the UK were historically associated with drinking infected unpasteurised cows' milk (Gallagher and Jenkins 1998, Grange 2001). Pasteurisation of milk has effectively reduced exposure to *M bovis* for many people, but there is still a risk of infection for people whose occupation involves close contact with tuberculous animals; these cases usually present as pulmonary TB (Gallagher and Jenkins 1998, Cousins and Dawson 1999, Grange 2001, Thoen and others 2006, de la Rúa-Domenech 2006). Cutaneous TB is an uncommon presentation of *M bovis* infection, representing approximately 3 per cent of human *M bovis* infections diagnosed between 2000 and 2005 in the UK (Health Protection Agency Centre for Infections 2006) and seven of 148 (4.7 per cent) of Australian cases between 1970 and 1994 (Cousins and Dawson 1999). An occupational association with cutaneous TB caused by *M bovis* is reflected in the historical synonym 'Butcher's wart' (Grange 2001). Specific groups reported as being at risk for *M bovis*-associated cutaneous TB include cattle workers (Gallagher and Jenkins 1998, Bravo and Gotuzzo 2007), trappers handling infected possums in New Zealand (Gallagher and Jenkins 1998), veterinarians exposed during surgery and postmortem examination (de la Rúa-Domenech 2006) and laboratory technicians exposed through accidental self-inoculation (Ho and others 2006). The occupational risk for veterinary pathologists was highlighted in a case report from New Zealand, where accidental inoculation occurred during postmortem examination of a tubercu-

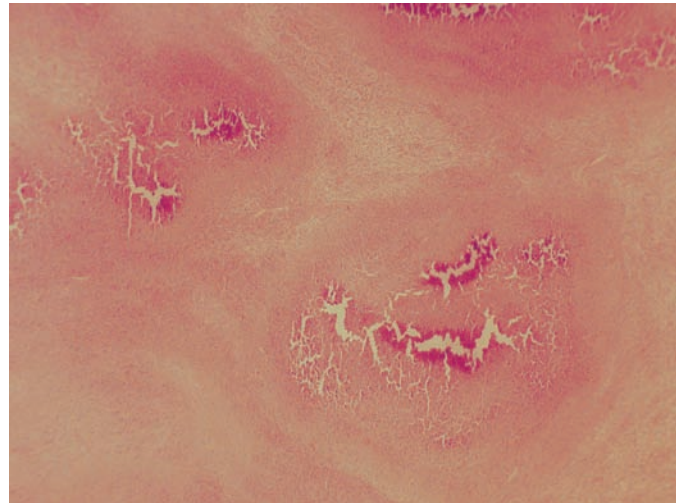


FIG 2: Thoracic lymph node of an alpaca cria, showing granulomatous and necrotising lymphadenitis. Haematoxylin and eosin. x40

lous possum (Cooke and others 2002). The exposed person developed clinical tenosynovitis four months later, but was successfully treated with surgical debridement and combined isoniazid, rifampicin and ethambutol therapy.

The present case of *M bovis* infection and cutaneous TB in a veterinary surgeon is possibly the first associated with an infected South American camelid. Although the veterinary surgeon had regular contact with other animal species, including cattle, these were not considered to be likely sources of infection, as she routinely wore protective gloves (the exception having been at the time of euthanasing the alpaca), and never came into contact with tuberculous tissues from other species. Contact with a tuberculous alpaca cria, subsequent identification of a member of the *M tuberculosis* complex in its affected tissues by PCR and the absence of known contact with other infected material provide strong circumstantial evidence to suggest that the alpaca was the source of infection. Opportunities for infection were: repeated close contact with the infected animal over several days, including an invasive thoracocentesis; contamination of the hands with blood during venepuncture for euthanasia; and contact with tuberculous tissues at postmortem examination even though gloves were worn. Although a traumatic entry point for infection might be considered necessary to establish local infection, obvious trauma is not always reported (Barbagallo and others 2002). The veterinary surgeon in the present case had no recollection of accidental inoculation during any procedure involving the infected alpaca, and no abrasions were observed on her skin during the contact period.

The *M bovis* spoligotype isolated from the veterinary surgeon is one of the most common types isolated from infected UK animals (de la Rúa-Domenech 2006). VNTR allows finer discrimination of *M bovis* strains and is an important tool in establishing the geographical location where infection occurs. The VNTR pattern identified in the present case is commonly recognised from animals in the region of south-west England where the veterinary surgeon worked (VLA, unpublished data), further supporting the likelihood of occupational exposure.

Although several infected herds of South American camelids have been identified in the UK (VLA, unpublished data), the associated zoonotic risk of TB is not well recorded. Extensive pulmonary pathology is a common feature of *M bovis*-infected South American camelids (Barlow and others 1999, Twomey and others 2007, 2009) and was seen in the alpaca cria reported here. Aerosol transmission is therefore a possible route of infection for animal handlers. Although there are no previous published reports of human TB associated with South American camelids, to the authors' knowledge, a presumptive diagnosis of infection was made in a human contact from a heavily infected Netherlands herd based on a strongly positive Mantoux reaction. The patient was subsequently given prophylactic anti-TB therapy (Dinkla and others 1991). Given the increasing UK population of

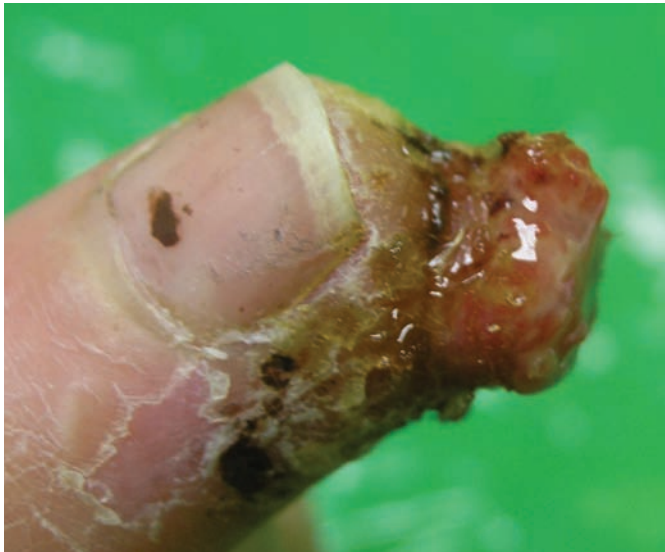

FIG 3: Verrucous lesion of cutaneous tuberculosis on the thumb of a veterinary surgeon

South American camelids (Davis and others 1998, D'Alterio and others 2006) and the potential for them to be infected with members of the *M tuberculosis* complex, public health workers should be aware of the zoonotic risk for people with close contact with these animals, particularly owners, veterinary surgeons, postmortem examination attendants, and members of the public visiting open farms or zoological collections. Since the case reported here was diagnosed, revised legislation introduced in 2006 under the Tuberculosis (England) Order has made it obligatory to notify any suspicious tuberculous lesions in carcasses of all farmed species and pet mammals (Monies and others 2006).

The authors recommend that cutaneous TB is considered early in the differential diagnosis of skin lesions where occupational exposure to tuberculous animals has been reported. The low prevalence of this presentation may result in misdiagnosis (Hruza and Snow 1990). Failure to recognise the tuberculous basis of this condition has not always been detrimental to the long-term health of the patient, as demonstrated by a case of *M bovis*-associated cutaneous TB that remained incidental and undiagnosed for over 40 years (Hruza and Snow 1990). In contrast, the present report suggests that cutaneous TB can become a significant clinical condition, especially if an aetiologically specific early diagnosis is not made, and this can result in inappropriate treatment.

### Acknowledgements

Molecular typing of the human *M bovis* isolate and PCR testing of the alpaca samples were funded by Defra under contract SB 4510.

### References

- BARBAGALLO, J., TAGER, P., INGLETON, R., HIRSCH, R. J. & WEINBERG, J. M. (2002) Cutaneous tuberculosis: diagnosis and treatment. *American Journal of Clinical Dermatology* **3**, 319-328
- BARLOW, A. M., MITCHELL, K. A. & VISRAM, K. H. (1999) Bovine tuberculosis in llama (*Lama glama*) in the UK. *Veterinary Record* **145**, 639-640
- BRAVO, F. G. & GOTUZZO, E. (2007) Cutaneous tuberculosis. *Clinics in Dermatology* **25**, 173-180
- COOKE, M. M., GEAR, A. J., NAIDOO, A. & COLLINS, D. M. (2002) Accidental *Mycobacterium bovis* infection in a veterinarian. *New Zealand Veterinary Journal* **50**, 36-38
- COUSINS, D. V. & DAWSON, D. J. (1999) Tuberculosis due to *Mycobacterium bovis* in the Australian population: cases recorded during 1970-1994. *International Journal of Tuberculosis and Lung Disease* **3**, 715-721
- D'ALTERIO, G. L., KNOWLES, T. G., EKNAES, E. I., LOEVLAND, I. E. & FOSTER, A. P. (2006) Postal survey of the population of South American camelids in the United Kingdom in 2000/01. *Veterinary Record* **158**, 86-90
- DAVIS, R., KEEBLE, E., WRIGHT, A. & MORGAN, K. L. (1998) South American camelids in the United Kingdom: population statistics, mortality rates and causes of death. *Veterinary Record* **142**, 162-166
- DE LA RUA-DOMENECH, R. (2006) Human *Mycobacterium bovis* infection in the United Kingdom: incidence, risks, control measures and review of the zoonotic aspects of bovine tuberculosis. *Tuberculosis* **86**, 77-109
- DINKLA, E. T. B., HAAGSMA, J., KUYVENHOVEN, J. V., VEEN, J. & NIEUWENHUIJS, J. H. M. (1991) Tuberculosis in imported alpacas - a zoonosis - now what? *Tijdschrift voor Diergeneeskunde* **116**, 454-460 (In Dutch)
- GALLAGHER, J. & JENKINS, P. A. (1998) Mycobacterial diseases. In *Zoonoses: Biology, Clinical Practice, and Public Health Control*. Eds S. R. Palmer, Lord Soulsby, D. I. H. Simpson. Oxford University Press. pp 155-164
- GRANGE, J. M. (2001) *Mycobacterium bovis* infection in human beings. *Tuberculosis* **81**, 71-77
- HEALTH PROTECTION AGENCY CENTRE FOR INFECTIONS (2006) Focus on Tuberculosis: Annual Surveillance Report 2006 - England, Wales and Northern Ireland. Health Protection Agency Centre for Infections
- HEWINSON, R. G., VORDERMEIER, H. M., SMITH, N. H. & GORDON, S. V. (2006) Recent advances in our knowledge of *Mycobacterium bovis*: a feeling for the organism. *Veterinary Microbiology* **112**, 127-139
- HO, C. K., HO, M. H. & CHONG, L. Y. (2006) Cutaneous tuberculosis in Hong Kong: an update. *Hong Kong Medical Journal* **12**, 272-277
- HRUZA, G. J. & SNOW, S. N. (1990) Cutaneous *Mycobacterium bovis* infection of 40 years' duration. *Archives of Dermatology* **126**, 123-124
- KAMERBEEK, J., SCHOOLS, L., KOLK, A., VAN AGTERVELD, M., VAN SOOLINGEN, D., KUIJPER, S., BUNSCHOTEN, A., MOLHUIZEN, H., SHAW, R., GOYAL, M. & VAN EMBDEN, J. (1997) Simultaneous detection and strain differentiation of *Mycobacterium tuberculosis* for diagnosis and epidemiology. *Journal of Clinical Microbiology* **35**, 907-914
- MONIES, B., JAHANS, K. & DE LA RUA, R. (2006) Bovine tuberculosis in cats. *Veterinary Record* **158**, 245-246
- O'REILLY, L. M. & DABORN, C. J. (1995) The epidemiology of *Mycobacterium bovis* infections in animals and man: a review. *Tubercle and Lung Disease* **76** (Suppl 1), 1-46
- ROBERT, J., BOULAHBAL, F., TRYSTRAM, D., TRUFFOT-PERNOT, C., DE BENOIST, A. C., VINCENT, V., JARLIER, V. & GROSSET, J. (1999) A national survey of human *Mycobacterium bovis* infection in France. Network of Microbiology Laboratories in France. *International Journal of Tuberculosis and Lung Disease* **3**, 711-714
- SMITH, N. H., KREMER, K., INWALD, J., DALE, J., DRISCOLL, J. R., GORDON, S. V., VAN SOOLINGEN, D., HEWINSON, R. G. & SMITH, J. M. (2006) Ecotypes of the *Mycobacterium tuberculosis* complex. *Journal of Theoretical Biology* **239**, 220-225
- TAYLOR, G. M., WORTH, D. R., PALMER, S., JAHANS, K. & HEWINSON, R. G. (2007) Rapid detection of *Mycobacterium bovis* DNA in cattle lymph nodes with visible lesions using PCR. *BMC Veterinary Research* **3**, 12
- TEMPEST, E., CLOSE, R., OLIVER, I. & EJIDOKUN, T. (2008) South West Enhanced Tuberculosis Surveillance Regional Report 2007 and Outcome Surveillance 2006. Health Protection Agency (South West)
- THOEN, C., LOBUE, P. & DE KANTOR, I. (2006) The importance of *Mycobacterium bovis* as a zoonosis. *Veterinary Microbiology* **112**, 339-345
- TWOMEY, D. F., CRAWSHAW, T. R., ANSCOMBE, J. E., FARRANT, L., EVANS, L. J., MCELLIGOTT, W. S., HIGGINS, R. J., DEAN, G., VORDERMEIER, M., JAHANS, K. & DE LA RUA-DOMENECH, R. (2007) TB in llamas caused by *Mycobacterium bovis*. *Veterinary Record* **160**, 170
- TWOMEY, D. F., CRAWSHAW, T. R., FOSTER, A. P., HIGGINS, R. J., SMITH, N. H., WILSON, L., MCDEAN, K., ADAMS, J. L. & DE LA RUA-DOMENECH, R. (2009) Suspected transmission of *Mycobacterium bovis* between alpacas. *Veterinary Record* **165**, 121-122